

**CASE REPORT****THORACIC SPINA BIFIDA**

Michael Tilahun\*

**ABSTRACT**

*We report a male newborn who was admitted to our NICU department after being referred from St. Gebriel general hospital as a case of respiratory distress. We have found accidentally a thoracic vertebral defect, a very rare vertebral abnormality that we recognized in the x-ray imaging performed for the study of the lung parenchyma.*

**Key words:** thoracic, NICU, Respiratory distress

**INTRODUCTION**

Spina bifida (SB) is the incomplete closure of the posterior components of the vertebrae because of a developmental disorder. In classical classification, SB has two types: closed (spina bifida occulta, SBO) and open (spina bifida aperta, SBA). Some abnormalities, such as defects in the vertebral components, tufts of hair on the skin, and nevus, are observed in SBO; however, a sac is not observed [1-3].

**Case report**

A male newborn born from a 38years old Para II Abortus III mother at GA of 38+3 weeks via Cesarean section (C/S) indication being gestational diabetes and macrosomia at term. Mother had Antenatal Care follow up at St. Gebriel general hospital and pregnancy was complicated by raised blood sugar. The mother was on oral hypoglycemic agent (Metformin) during pregnancy but she had poor glycemic control. Finally, she was put on insulin with sliding scale. After delivery the neonate developed respiratory distress and was referred to our hospital for NICU care.

On presentation to our hospital, the neonate is

in respiratory distress with respiratory rate of 30 per minute with grunting. Saturation of Oxygen was 97-100 % with Continuous Positive Airway Pressure at 3 cm depth and 8 liters. Weight was 4000gm, head circumference (HC) 36cm and length was 51cm. The HC and length are appropriate for gestational age (AGA) but the weight was large for gestational age (LGA).

On chest examination, there was inter- costal and sub costal retraction. Had crepitations on the basal anterior chest bilaterally. On neurological examination, he was conscious, complete moro, strong grasp and normal tone but absent suckling reflex. With an assessment of Term (GA = 38 + 3 weeks ), LGA (Macrosomia), Infant of Diabetic Mother, Cesarean delivery for gestational DM and macrosomia ), Respiratory distress secondary to Congenital pneumonia to rule out Transient Tachypnea of the Newborn (TTN), he was treated with maintenance fluid and antibiotics (Ampicillin and Gentamycin). The CPAP was continued; later he was put on intra nasal oxygen which latter was discontinued.

\* Hallelujah General. Hospital  
Corresponding author: mtelahun@yahoo.com

Investigations including chest x-ray were done.

After 7days of hospital stay, the neonate was discharged home improved with appointment.

chest -x ray showed T1- T6 vertebral body defects and left basal lung parenchymal infiltrates.

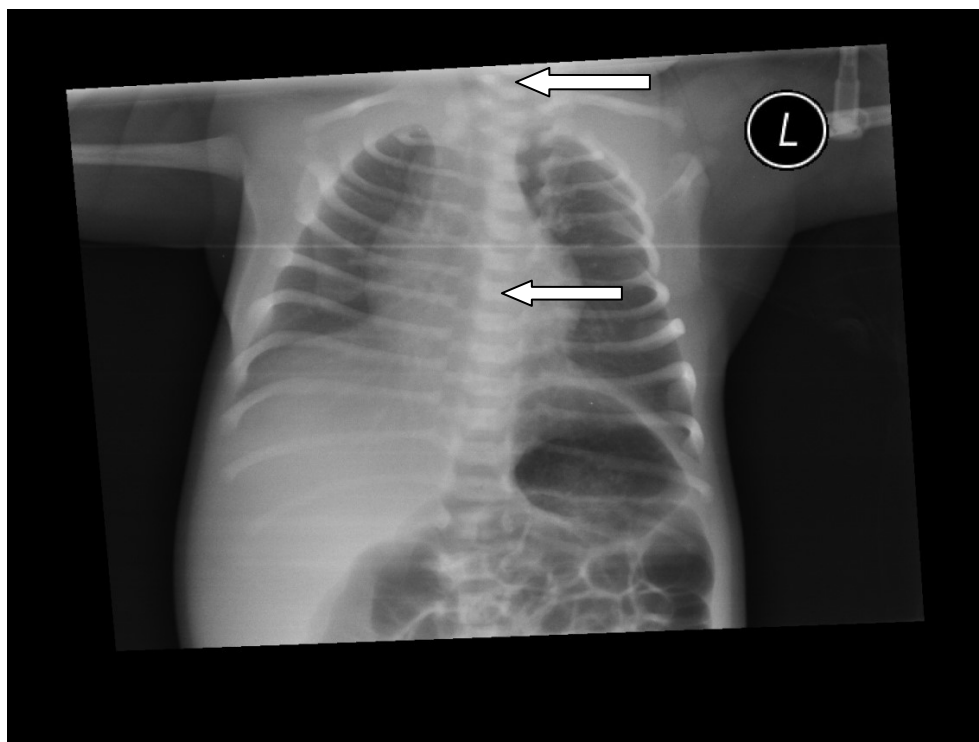


Fig-1 Arrows showing unfused vertebra from T1- T6

### Discussion

Congenital anomalies of spine are quite common and most of these anomalies are localized at cervical and lumbar spine. Conversely, the localization of these anomalies at thoracic spine is rare. Usually, spine deformities can be divided into congenital and acquired forms. Congenital forms are mainly divided into 2 types: segmentation and development defects. Unilateral unsegmented bars and bilateral segmentation defects belong to the first group. On the other side, developmental

defects include hemi vertebrae and failure of fusion of neural tube which includes, in turn, the simple cleft of the posterior arch of the vertebrae (spina bifida occulta) and spina bifida [4].

NTDs are the most common malformations having an incidence of 1-5 per 1000 live births [5].

Spina bifida is a Latin term which refers to a posterior opening in the vertebrae associated to a spinal cord involvement. Spina bifida results from a neural tube closure anomaly

(incomplete closure of posterior vertebral arch) associated with lesion of spinal cord [6,7,8]. It is due to embryological anomaly occurred in the 4th week. It is generally located in the lumbar or sacral regions and extends over 2-4 vertebrae. . More precisely, spina bifida would be the result of a disorder in the metabolism of folates. Several genes are thought to be responsible of the malformation, such as the MTHR (methylen tetrahydrofolate reductase) gene located in 1p36.3 [7, 9] or PAX3 structure gene [8]. Zinc metabolism has also been incriminated.

In case of spina bifida occulta, the anomaly is often discovered by chance. Hair on the back midline is a classical sign of spina bifida [6]. Spina bifida occulta is usually found in the areas C1 and C6 [7]. Standard cervical spine X-rays are a good source of information. These anomalies can occur at any level of the spine, although it is more frequently found at the lumbo-sacral level and more rarely in the cervical area.[10]

In this report, we describe a case of asymptomatic simple spina bifida occulta. The most affected vertebrae are mainly T1 to T6.

## REFERENCES

1. Pico EL, Wilson PE, Haas R. Spina bifida. In: Alexander MA, Matthews DJ, editors. Pediatric rehabilitation. 4th ed. New York, USA: Demos Medical Publishing;2010.p. 199-230.
2. Rossi A, Biancheri R, Cama A, Piatelli G, Ravegnani M, Tortori-Do-nati P. Imaging in spine and spinal cord malformations. Eur J Radiol 2004; 50:177-200.
3. Copp AJ, Greene ND. Neural tube defects--disorders of neurulation and related embryonic processes. Wiley Interdiscip Rev Dev Biol 2013; 2:213-27.

## Conclusion

We have described a rare case of thoracic vertebral failure of fusion at T1- T6 level in a neonate who was admitted to our NICU for management of respiratory distress during chest X ray investigation for lung parenchymal examination. We think that this case report may be helpful to radiologists to look for such uncommon findings when they are evaluating patients with non specific neurological symptoms; such abnormalities may result in musculoskeletal problems such as foot deformities; spina bifida may manifest with leg/ hand weakness, numbness or clumsiness, plus non specific neurological pain and for neurosurgeons to consider this singular finding.

## Acknowledgment

I would like to thank Mesfin Tsigie, MD, Expert Radiologist for taking interest in the case and giving the appropriate radiological comment. Also I would like to extend my gratitude to Ms Solome Mesfin for her assistance in obtaining and organizing the records for this case report.

4. Postacchini F., Ferretti A., Ippolito E. Collo e tronco. In: Delfino Antonio., editor. *Ortopedia e Traumatologia & Medicina Fisica e Riabilitativa*. 2nd edn. Antonio Delfino Editore medicina-scienze; Rome: 2009. pp. 239–40.
5. JD Cragan, HE Roberts, LD Edmonds. Surveillance for anencephaly and spina bifida and impact of prenatal diagnosis in United States. 1985-1994. *Mortal Morb Wkly Rep*. 1995;44; 44:113
6. Spina Bifida. Office of communication and Public Liason. National Institute of Neurological disorders and Stroke. National Institute of Health. Department of health and human services. Bethesda, Maryland 20852- 2540. NIH publication number 13- 309. September 2013, p. 3.
7. Northrup HVK. Spina bifida and other neural tube defects. *Curr Probl Pediatr* 2000; 30:313-32.
8. Padmanabhan R. Etiology, pathogenesis and prevention of neural tube defects. *Congenital Anomalies* 2006;46:55-67.
10. Van Der Put NM. et al. Mutated Methylenetetrahydrofolate reductase as a risk factor for spina bifida. *The Lancet* 1995; 346:1070-1.
11. Ferri, Fred F. (2016). *Ferri's Clinical Advisor 2017: 5 Books in 1*. Elsevier Health Sciences. p. 1188.e2. ISBN 9780323448383