

CASE REPORT

CONGENITAL NASAL PYRIFORM APERTURE STENOSIS

MICHAEL TELAHUN¹

INTRODUCTION

Neonatal nasal obstruction due to congenital nasal pyriform aperture stenosis is very rare and uncommon. The usual clinical presentation is respiratory distress, cyclic cyanosis, apneas, and feeding difficulties. A bony overgrowth of the maxillary nasal processes is thought to be responsible for this deformity. The diagnosis is suggested by history and physical examination; however, it should be confirmed through radiological evaluation i.e., a CT scan of the nasal cavity. It has been suggested that a pyriform aperture width less than 8 mm in a term infant is diagnostic of CNPAS (Congenital Nasal Pyriform Aperture Stenosis). This anomaly has been reported as an isolated feature or can be associated with craniofacial or central nervous system anomalies. Surgery is indicated in cases of severe respiratory distress, feeding difficulties, and when there is no benefit with conservative methods. We are reporting a case of a male baby diagnosed with CNPAS and was managed in our Hallelujah General Hospital.

CASE REPORT

A pre-term male baby, second child of non-consanguineous parents was born by emergency caesarian section (C/S) because of pre-

term labor and previous C/S scar. The birth weight was 2.1 kg and the neonate had an appearance, pulse, grimace, activity, respiration (APGAR) score of 8 and 9 at one 5th minutes respectively. The neonate is referred to our NICU (Neonatal Intensive Care Unit) because he developed fast breathing, grunting and retractions following delivery.

During his stay in the NICU baby had persistent fast breathing with desaturation when he is put off CPAP (Continuous positive airway pressure). After 72 hours of admission his condition started to improve except for the fast breathing (RR ranging between 62-66/minute) and intermittent desaturation. For initiation of trophic feeding naso-gastric (NG) tube was inserted because he had difficulty of suckling with his mouth. There was resistance during the insertion of the NG tube on both nostrils more on the right side.

After this the possibility of choanal atresia was considered. On examination the infant had no dysmorphic features. The external nasal pyramid and nasal vestibular opening were normal and test for nasal breathing with cotton was done and there was no movement of the cotton seen more on the right side suggesting obstruction.

All the cranial nerves were normal. There was no coloboma of eye and the cardiovascular examination was normal. Other investigations like chest X-ray, Echocardiogram and Brain CT were also normal.

The CT scan of the Nose and paranasal si-

nuses showed bilateral nasal aperture stenosis with no evidence of bony or membranous choanal atresia.

Preoperative CT scan showed narrowing of pyriform aperture.

Figure 1

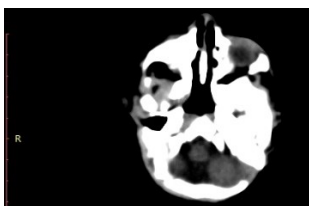


Figure 2

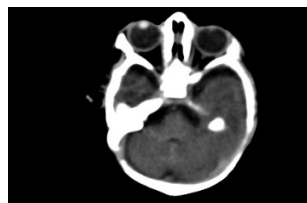

Figure 3

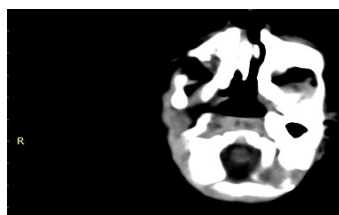
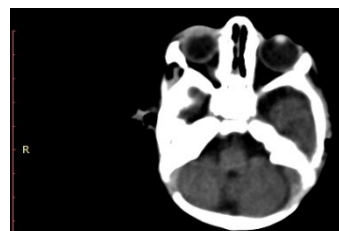


Figure 4

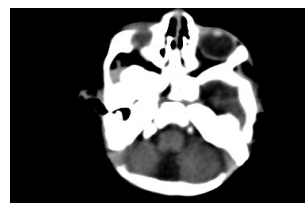

Figure 5



On 20/05/17 the patient was taken to operation room after written consent of the family and put in supine position after wrapping with cotton, draped and anesthetized. Local anaesthesia lidocaine with strength of 1:200000 injected sublabially after cleaning oral cavity well. Incision was made sublabially about 5 mm away from the gingival sulcus up to subperiosteum and flap is raised up to nasal orifice. Flap also raised in nasal cav-

ity and prominent bone on both sides is curetted and removed. Nasal cavity became patent and number 3 endotracheal tube stented and surgical wound closed in layer. After extubation the infant was able to maintain saturation at room air and there was no cyclical cyanosis and apneic spells. Then the patient was transferred to intensive care unit after being fully awake.

After 2 weeks both stents were removed and repeat nasal endoscopy was done which showed bilateral adequate nasal cavity. The infant remained comfortable at room air and was able to bottle feed and started to gain weight. The patient is on regular follow up for last two weeks and is doing well.

DISCUSSION

The nasal pyriform aperture is a pear-shaped bony inlet of the nose formed by the nasal and maxillary bones. The origin and embryological development of CNPAS remains undetermined; but it arises in the fourth month of fetal development because of an overgrowth of the nasal process of the maxilla and may present as an isolated condition or in association with other congenital disorders. The narrowing of the nasal aperture results probably from a bony overgrowth of the maxillary nasal processes during maxillary ossification (1).

Infants with CNPAS present at birth or shortly thereafter with severe nasal obstruction leading to noisy breathing and respiratory distress that worsens with feeding and improve with crying. It can occur in isolation or in association with other malformations (2).

CNPS clinically presents with unspecific symptoms, such as episodes of cyanosis, inspiratory stridor, sternal retraction, thoracic asymmetry, hypoxemia, and acidosis (3,4).

Congenital nasal pyriform aperture stenosis is a rare but life threatening nasal obstruction in neonates as they are nasal obligatory breathers (5, 6). Bony obstruction of nasal cavity either unilaterally or bilaterally is

commonly due to choanal atresia (7). CNPAS occurs at a frequency of about one fourth to one-third of choanal atresia (8).

In addition to respiratory manifestations CNPAS can also present with feeding problems and sleep difficulties (9).

CNPAS has been described as an isolated anomaly or can be associated with a range of craniofacial and brain anomalies (10-12). The presence of associated brain, pituitary and chromosomal anomalies should be excluded by the mean of magnetic resonance imaging, endocrinologic and genetic evaluation.

The inability to pass a 5F catheter and a radiographically measured pyriform opening < -10 mm in a full-term infant are considered diagnostic (13-15).

CONCLUSION

CNPAS is a rare case of neonatal nasal obstruction. Early prompt recognition of neonatal nasal obstruction and timely management is necessary to relieve respiratory distress. It's better to consider this unusual presentation of neonatal nasal obstruction in those newborns for whom there is no strong explanation for respiratory distress. Simple NG tube insertion can make the diagnosis of this rare cause likely.

In all cases of CNPAS, a multidisciplinary approach involving ENT specialists is required to rule out other craniofacial or mid-brain abnormalities.

REFERENCE

1. Brown OE, Myer CM, III, Manning SC. Congenital nasal pyriform aperture stenosis. *Laryngoscope* 1989. Jan; 9(1):86-91
2. Kenman MA. "Congenital Disorders of Nose" in Nelson Text Book of Pediatrics, Kleigman, Stanton, St Geme, Schor, eds, Elsevier, Philadelphia, 20th ed., 2016: 2937-38
3. Losken A, Burstein FD, Williams JK: Congenital nasal pyriform aperture stenosis: diagnosis and treatment. *Plast Reconstr Surg* 2002, 15:1506-10.
4. Hui Y, Friedberg J, Crysedale WS: Congenital nasal pyriform aperture stenosis as a presenting feature of holoprosencephaly. *Int J Pediatr Otorhinolaryngol* 1995, 31:263-74.
5. Van Den Abbeele T, Triglia JM, François M, Narcy P. Congenital nasal pyriform aperture stenosis: diagnosis and management of 20 cases. *Ann Otol Rhinol Laryngol* 2001. Jan; 110(1):70-75
6. Lowe LH, Booth TN, Joglar JM, Rollins NK. Midface anomalies in children. *Radiographics* 2000. Jul-Aug; 20(4):907-22
7. Pereira KD, Wang BS. Congenital nasal pyriform aperture stenosis. *Oper Tech Otolaryngol Head Neck Surg.* 2005;16(3): 194-97.
8. Thomas EM, Gibikote S, Panwar JS, Mathew J. Congenital nasal pyriform aperture stenosis: a rare cause of nasal airway obstruction in a neonate. *Indian J Radiol Imaging.* 2010; 20(4):266
9. Tagliarini JV, Nakajima V, Castilho EC. Congenital nasal pyriform aperture stenosis. *Rev Bras Otorrinolaringol.* 2005; 71(2):246-49
10. Tavin E, Stecker E, Marion R. Nasal pyriform aperture stenosis and the holoprosencephaly spectrum. *Int J Pediatr Otorhinolaryngol* 1994. Jan; 28(2-3):199-204
11. Lo FS, Lee YJ, Lin SP, Shen EY, Huang JK, Lee KS. Solitary maxillary central incisor and congenital nasal pyriform aperture stenosis. *Eur J Pediatr* 1998. Jan; 157(1):39-44
12. Pereira K, Wang B: Congenital nasal pyriform aperture stenosis. *Oper Tech Otolaryngol* 2005, 16:194-97
13. Tavin E, Stecker E, Marion R: Nasal pyriform aperture stenosis and the holoprosencephaly spectrum. *Int J Pediatr Otorhinolaryngol* 1994, 28:199-204.
14. Tagliarini J, Nakajima V, Castilho E: Congenital Nasal Aperture Stenosis. *Rev Bras Otorrinolaringol* 2005, 71:246-49.
15. Brown OE, Myer CM, Manning SC. Congenital nasal pyriform aperture stenosis *Laryngoscope* 1989;99:86-99