

Acid fast bacilli in aspiration smears from tuberculous patients

Wondwossen Ergete, Alemayehu Bekele

Abstract: Fine-Needle aspiration (FNA) has been used in the diagnosis of tuberculous adenitis or extrapulmonary tuberculosis of extranodal sites for more than ten years in the Tikur Anbessa Teaching Hospital, Department of Pathology, Faculty of Medicine, Addis Ababa University. The purpose of this study was to see the correlation between the cytomorphologic diagnosis and the subsequent demonstration of acid fast bacilli in the smear and also to know the overall acid fast bacilli (AFB) positivity. A cross sectional study, involving a total of 205 consecutive patients diagnosed to have tuberculosis by cytomorphology (FNA) between mid 1996 and early 1997 were included in the study. The May-Grunwald Giemsa stained smears were classified into three categories: Epithelioid granuloma without caseous necrosis, Epithelioid granuloma with caseous necrosis, Abscess and/or Caseous necrosis. There were 131 (63.9%) cases with granuloma with caseous necrosis, 67(32.7%) cases with abscess and/or caseous necrosis, and only seven (3.4%) cases with granuloma without caseous necrosis. The AFB positivity as stained by Ziehl Neelsen stain was 99 (75.6%) in granuloma with caseous necrosis, 46(68.7%) in tuberculous abscess and/or caseous necrosis and 2(28.5%) in granuloma without necrosis. The overall acid fast positivity was 71.7%. This study confirmed that FNA alone is helpful enough in making a diagnosis of tuberculosis in most of the cases. We recommend that the evaluation of all fine needle aspiration samples from suspected cases of tuberculosis should include staining for AFB for confirmation and in particular for cases of abscess and necrosis as part a diagnostic step. However, culture of the aspirate is still required when the smears are AFB negative and cytologically equivocal whenever it is available. [*Ethiop. J. Health Dev.* 2000;14(1):99-104

Introduction

Tuberculosis remains a major public health problem worldwide. A definitive and accurate diagnosis of tuberculosis is important because satisfactory results can be achieved with chemotherapy alone, obviating surgery. Recently, FNA has provided an alternative and easy procedure for collection of material for cytomorphologic and bacteriologic examination (1,2). The characteristic cytomorphologic feature of tuberculosis is granulomatous inflammation. Cytologically, granulomatous inflammation is the clustering of epithelioid cells in a lymphoid background. The epithelioid cells have an elongated nuclei with fine granular chromatin and a small nucleoli.

Multinucleated foreign body or Langhans Giant Cells and a caseous necrotic material may or may not be present (1). Granulomatous inflammation is not only a manifestation of tuberculosis but also of a variety of diseases, such as leprosy, mycoses, sarcoidosis, to mention only a few. In developing countries tuberculosis is a rampant disease and, most cases cytologically or histologically presenting as granulomatous inflammation are presumed to be and are treated as tuberculosis (1,2). FNA has been used as the first line diagnostic step in making a diagnosis of tuberculosis lymphadenitis or other extranodal tuberculosis in extrapulmonary sites for more than ten years in the Department of Pathology. The diagnosis of tuberculosis by FNA is based on cytomorphologic demonstration of granulomatous inflammation with or without caseous necrosis. Some times caseous necrosis

or abscess which is compatible with tuberculosis is diagnosed if the epithelioid cells are absent from aspirated smear. FNA avoids the physical and psychological trauma occasionally encountered after open surgical biopsy. It is convenient for the patient and the physician alike, useful for outpatients, and relatively painless(2). Prasad et al reported sensitivity and specificity rates of FNA in making a diagnosis of tuberculosis as 83.3% and 94.3%, respectively (3). The reported AFB positivity rate using Ziehl Neelsen Stain in aspiration smears was in the range of 40-56% (4,5). Ziehl Neelsen staining on smears from aspirates diagnosed to be tuberculous in aetiology has never been done routinely in this Department to confirm the cytomorphologic diagnosis of tuberculosis.

This study presents an analysis of the findings in the FNA smears from 205 cases of tuberculous patients diagnosed in the FNA unit. The purpose of this study was to see the correlation between the FNA cytomorphologic diagnosis of tuberculosis and subsequent demonstration of AFB in the smear and overall AFB positivity.

Methods

A cross sectional hospital-based study was conducted in Tikur Anbessa Teaching Hospital, Department of Pathology, Faculty of Medicine, Addis Ababa University. All consecutive aspirates obtained from patients referred to the FNA unit between mid 1996 and early 1997 and diagnosed by FNA to have tuberculosis were included in this study. The aspirate was taken mainly from superficial lymph nodes and occasionally from other accessible sites. The FNA had been performed by residents or members of the Department using a 20-22 gauge needle with an attached 10 ml syringe which was mounted on an aspiration cameco gun. During each pass, the needle was moved throughout the lesion several times while aspirating. Varying sites of lymphadenopathy (i.e. cervical, axillary, inguinal) and occasional extranodal areas were aspirated. The aspirated material was expressed on to glass slides and smeared. In each case, at

least, two smears were set aside for May Grunwald-Giemsa-staining and one for Ziehl Neelsen staining (6). The May Grunwald-Giemsa and Ziehl Neelsen stained smears were examined by two pathologists at the same time. The Ziehl Neelsen stained smears were examined with 100x oil immersion lens. The final consensus diagnosis was accepted for the analysis. Both negative and positive control smears were stained concurrently to assess the true negative and positive reactions of the staining procedure respectively.

The May-Grunwald-Giemsa stained smears were classified into three categories based on their morphologic features (7) as follows:

1. Epithelioid granuloma without caseous necrosis. Groups of epithelioid cells were found along with a viable number of lymphoid cells. Foreign body or Langhans Giant Cells may or may not be present
2. Epithelioid granuloma with caseous necrosis. In addition to epithelioid cells, the smear contained clumps of amorphous acellular debris or caseous necrotic material. Lymphocytes, Langhans Giant Cells and neutrophils may be found.
3. Necrotic material without epithelioid granuloma. Clumps of amorphous acellular material was seen. This was described as degenerated granulomas (caseous necrosis) and/or liquefied necrotic material with marked degenerating and viable polymorphonuclear infiltration without epithelioid granuloma. This was described as tuberculous abscess. Gram stain or culture for the bacteria was not done. Diagnosis of tuberculosis in such cases was based on the cytomorphologic features mentioned above and absence of clinical signs and symptoms suggestive of pyogenic abscess.

Simple descriptive statistical methods and microsoft Excel version 5.0 were used to analyse the results.

Results

A total of 209 [cases who fulfilled the study criteria] consecutive patients with the diagnosis of tuberculosis by cytomorphology were included in the study. Only four FNA

specimens (1.9%) were excluded from the study because Ziehl Neelsen stained smears had many stain precipitates obscuring the background. There were 87 males and 118 females making the male to female ratio 0.7:1. The youngest was nine months old and the oldest was 65 years old. The mean and median age was 22.8 and 23 years old respectively. As shown in Figure 1, the peak age of tuberculosis was between 20-29 years. Seventy nine percent of the cases were in the 10-39 year age bracket. Tuberculous lymphadenitis was diagnosed in 194 (94.6%) cases and the remaining 11(5.4%) cases were from extranodal extrapulmonary sites . Of those lymph nodes 152 were cervical, 28 axillary, and 14 inguinal. The rest (11 cases) were from extranodal sites (three chest wall, two each from iliac crest and breast, one each from back, testis, leg and abdominal wall).

necrosis (Table 1). There seems to be low AFB positivity in cases where granuloma without caseous necrosis was the cytomorphologic diagnosis even though the number of cases with this diagnosis was too small. The overall AFB positivity rate was 71.7%.

Table 1: The number of cases and rate of AFB positivity in three cytomorphologic categories, 1997

Category	No.		No. of AFB Positive %	
	No.	%	No.	%
Granuloma without necrosis	7	3.4	2	28.5
Granuloma with necrosis	131	63.7	99	75.6
Abscess &/or Necrosis	67	32.7	46	68.7
Total	205	100	147	71.7*

* overall AFB positivity rate

Discussion

FNA has been very useful in the diagnosis of tuberculosis as it was discussed in numerous studies (4,8,9,10). Tuberculosis accounted for more than 50% of patients subjected for FNA of the lymph nodes in the Department of Pathology (unpublished data). The rate of AFB positivity in aspiration smears of tuberculous lymphadenitis is between 40.6% and 56.4% (4, 5, 11, 12). The cytologic patterns described earlier show a wide variation in the frequency of AFB positivity. Acid fast bacilli positivity is low in epithelioid granuloma without necrosis (5.8 to 30%) but significantly higher in epithelioid granuloma with necrosis (32 to 64.7%) and highest in necrosis without epithelioid granuloma (48.5 to 77.4%) [5] . In our study the finding is comparable to the above rates even though it is slightly higher than the reported rates in cases with granuloma and caseous necrosis. In fact, the highest AFB positivity rate among granuloma with necrosis cases is unusual in this study compared to necrosis cases alone.

It appears that these groups are similar to the various stages of tissue response described in progressive tuberculous lesions of the lung: formation of epithelioid granuloma, necrosis in granuloma and liquefaction of necrotic foci with dissemination of the disease (13). Cases showing epithelioid granuloma with necrosis in the cytologic specimen pose no diagnostic

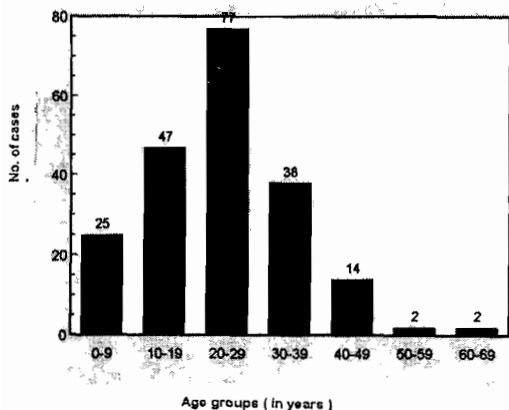


Figure 1: Age distribution of tuberculous patients diagnosed by FNA in the Department of Pathology, Faculty of Medicine, Addis Ababa University, September 1996-February 1997.

The majority of cases (131 or 63.9%) showed granuloma with caseous necrosis followed by 67(32.7%) abscess &/or caseous necrosis and 7(3.4%) granuloma without necrosis. The highest yield of AFB positivity was found in cases in which granuloma with necrosis was a cytomorphologic diagnosis (99 or 75.6%), followed by 46 (68.66%) positivity in abscess and/or caseous necrosis cases, 2(28.5%) in granuloma without caseous

difficulty. Moreover, the frequency of AFB positivity is high in this group (75.7%) in our series compared to 64.7% in Rajwanshi series (5). In cases having epithelioid granuloma without caseous necrosis, AFB positivity is usually low as it was seen in our finding even though the number of cases were too small. The reason for this could be that most of our patients present in the late stages of the disease process where caseous necrosis in granuloma is very common as it was described earlier. This was evident since 63.9% of our cases were grouped in this category. In such cases (granuloma without caseous necrosis), if the AFB is negative, other possibilities, such as sarcoidosis may be considered in the differential diagnosis. However, in developing countries where tuberculosis is very common, cases of epithelioid granuloma without necrosis should be considered as tuberculous lesion unless proved otherwise(5).

In smears containing necrotic material without epithelioid granuloma and, especially in cases with marked neutrophilic reaction diagnostic dilemma may arise if AFB stain and/or culture is not done. Fortunately, the frequency of AFB positivity is the highest in this group 68.7% in our series, 66% in sadanah series (11). So there is a need to do routinely Ziehl Neelsen staining in such cases to confirm the diagnosis of tuberculous. In the absence of Ziehl Neelsen staining these cases might have been missed as acute suppurative lymphadenitis or treated as a pyogenic abscess. The finding of abscess and purulent inflammation comprise a significant component of the histologic picture of tuberculous lymphadenitis in patients with acquired immuno-deficiency syndrome (AIDS) which may create a diagnostic challenge if Ziehl Neelsen Stain is not done (14,15,16). As shown earlier, with progressive deterioration of cellular immunity, patients with Human Immuno-deficiency Virus (HIV) tend to develop histopathologic pictures in which bacilli are present in great numbers, while the inflammatory response is far from the usual granulomatous pattern seen in tuberculosis without HIV infection. Inverse relationship

between the numbers of bacilli and the presence of well formed granuloma in subjects with HIV infection at varying degrees of immunodeterioration was described earlier (17). This unusual histopathology of tuberculosis in AIDS (i.e., abscess formation and numerous organisms) has been attributed to a compromised immune status and/or an inability to mount an adequate cellular immune response, which might be more effective than an influx of neutrophils against mycobacterial proliferation. In fact the majority of the patients in this study seem to have HIV-co-infection because of the following reasons: as the most frequent site of extrapulmonary tuberculosis in patients infected with HIV is a lymphnode, 94% of the cases had tuberculous lymphadenitis; the majority of patients were young adults where prevalence of HIV is at its peak, one third were noted to have abscess and/or caseous necrosis cytomorphologic picture which is commonly seen in HIV/AIDS patients.

When there is an infection by atypical mycobacteria in patients with AIDS, the cytologic and histologic picture is quite different. In FNA samples, many histiocytes are seen that the air-dried smears stained with Romanowsky methods appear like Gaucher Cells. Few to many clear, thin, slightly curved areas appear in these smears both in the background and within histiocytic cells, so called negative images. These areas which do not stain with water-based stains represent the atypical mycobacteria that are easily stained with acid fast stains and that usually occur in profusion in such smears. It is the waxy cell wall of these organisms that prevents penetration by water-based stains (18). Awareness of the above fact may reduce the chance of under diagnosis in AIDS patients.

It should be recognized that the microscopic detection of acid fast organisms irrespective of the stain used has a low sensitivity, because approximately 10,000 to 100,000 mycobacterial organisms per ml of sample are required for AFB to be detected on a cytologic specimen(15). Thus, all specimens (particularly the AFB negative) should be submitted for

culture. Mycobacterial culture has been shown to be a useful adjunct to routine cytology and AFB staining of cytologic smears. In a non-AIDS population, it increases sensitivity of AFB detection in FNA samples by as much as a factor of two (19). So culture for AFB can be used at least in cases negative by Ziehl-Neelsen Stain because it yields a higher rate of AFB positivity (10,14,19). Thus, submission of material for mycobacterial culture can significantly increase the sensitivity of FNA in the diagnosis of mycobacterial infection, especially in patients who are not at risk for AIDS. In addition, culture provides definite species identification and drug sensitivity pattern. Studies that have examined culture positive specimens for smear positivity have shown a range of 22 to 50% smear to culture correlation indicating low sensitivity of smears with respect to cultures (20).

Nowadays polymerase chain reaction (PCR) has been shown to be the most sensitive method for detection of AFB by amplifying the mycobacterial DNA fragments even in a minimal aspirate sample. Kim et al concluded that PCR is the most sensitive technique for the demonstration of *M. tuberculosis* in patients with clinically suspected cervical tuberculous lymphadenitis, who had AFB stain or culture negative cytology. But combined conventional and PCR methods as well as cytologic findings are of further help in the detection and characterization of *M. tuberculosis*(21).

In conclusion, Ziehl-Neelsen staining of Fine Needle aspirates in suspected cases of tuberculosis by cytomorphology gave encouraging results in confirming the diagnosis. This study confirmed that FNA alone is helpful enough in making a diagnosis of tuberculosis in the majority (71.7%) of the cases. Thus, Ziehl-Neelsen staining should be performed for confirmation and in particular for cases of abscess and necrosis as part of diagnostic step. However, submission of the aspirated material for both routine and mycobacterial cultures is still required when the smears are acid fast bacilli negative and cytologically equivocal whenever it is

available. It cannot be over emphasized that future studies should evaluate the effect of HIV co-infection on the degree of AFB positivity and cytomorphologic picture in tuberculous patients as most of these patients may have concomitant HIV infection.

Acknowledgement

The authors are very grateful to W/o Ethiopia Mekonnen for her time and help in typing the manuscript.

References

1. Lucas PF. Lymphnode smears in diagnosis of lymphadenopathy. *Blood* 1963;10:1030-54.
2. Finfer M, Perchik A, Burstein ED. Fine needle aspiration biopsy diagnosis of tuberculous lymphadenitis in patients with and without the Acquired Immunodeficiency Syndrome. *Acta Cytol*, 1991;35(3):325-32.
3. Prasad RR, Narasimhan R, Sankaran V, Veliath AJ. Fine needle aspiration cytology in the diagnosis of superficial lymphadenopathy, an analysis of 2418 cases, *Diagn Cytopathol*, 1996;15(5):382-6.
4. Das DK, Pant JN, Chachra KI, et al: Tuberculous lymphadenitis: Correlation of cellular components and necrosis in lymphnode aspirate with AFB positivity and bacillary count. *Indian J Pathol Microbiol*, 1990;33:1-10.
5. Rajwanshi A, Bhambhani S, Das DK. Fine needle aspiration cytology diagnosis of tuberculosis. *Diagn cytopathol*, 1987;3:13-6.
6. Bancroft JD, Stevens A, eds. *Theory and practice of histological techniques*, Spottswoolle Ballontyre Ltd. UK. 1980.
7. Dlip K Das, Lymph nodes. In: Maruluce Bibbo eds. *Comprehensive cytopathology* 2nd ed. Philadelphia. W.B. Saunders. 1997;707-9.
8. Bailey TM, Akhtar M, Ali MA: Fine needle aspiration biopsy in the diagnosis of tuberculosis. *Acta cytol* 1985;29:732-6.
9. Das Dk, Bhambhani S, Pant JN, et al. Superficial and deep seated tuberculous lesions. Fine needle aspiration cytology diagnosis of 574 cases. *Diagn cytopathol*, 1992;8:211-5.
10. Gupta SK, Chung TD, Sheikh ZA. *Air*

- abab NAR: Cytodiagnosis of tuberculous lymphadenitis. A correlative study with microbiologic examination. *Acta cytol*, 1993;37:329-32.
11. Sadanah MM, Janyaram G: Acid Fast bacilli in aspiration smear from tuberculous lymphnodes an analysis of 255 cases. *Acta Cytol*, 1981;31:17-9.
12. Radhika S, Rajwanshi A, Kochhor S, et al. Abdominal tuberculosis: Diagnosis by Fine needle aspiration cytology. *Acta Cytol*, 1993;37:673-8.
13. Anderson JR (ed): *Muir's Textbook of Pathology* 13th ed. London. Edward. Arnold. 199.
14. Qadri SMH, Akhar M, Ashraf M. Sensitivity of fine needle aspiration biopsy in the detection by Mycobacterial infections. *Diagn cytopathol*, 1991;7:142-6.
15. Nambuya A, Sewankambo N, Mugerwa J, et al. Tuberculous lymphadenitis associated with human immunodeficiency virus (HIV) in Uganda. *J Clin Pathol*, 1983;41:93-6.
16. Niedt GW, Schinella RA. Acquired Immunodeficiency Syndrome: Clinicopathologic study of 56 Autopsies. *Arch Pathol Lab Med*, 1985;109:727-34.
17. G.Di Perri, Cazzodori A, Vento S, et al. Comparative histopathologic study of pulmonary tuberculosis in HIV infected and non infected patients Tubercle and lung disease, 1996;3:244.
18. Maygarden SJ, Flanders EL. Mycobacteria can be seen as "negative images" in cytology smears from patients with AIDS. *Mod Pathol*, 1989;2:239-42.
19. Krishnaswami H, Job CK. The role of Ziehl Neelsen and Fluorescent stains in tissue sections in the diagnosis of tuberculosis. *Indian J Tuberc*, 1974;21:18-21.
20. Rickman TW, Moyer NP. Increased sensitivity of acid fast smears. *J clin Microbiol*, 1980;11:618-24.
21. Kim SS, Chung SM, Kim JN., Lee MA, Ha EH. *J Korean Med Sci* 1996;11(2):127-32.